

Current Recommendations for Optimum Treatment of Chemical Eye Burns

Moist swabs, compresses, phosphate buffers, and other forms of malpractice

Norbert Schrage

Ophthalmology Department, Municipal Hospital of Cologne-Merheim

In Germany, chemical eye burns are a common and recurring cause of long-term vision disorders and even blindness. Severe eye burns, however, have become less common thanks to sophisticated safety systems and high levels of safety standards in industrial workplaces. In contrast, extremely hazardous substances capable of causing severe

eye damage are readily available on the private consumer market.

Neither adequate preventive measures nor qualified first aid givers nor suitable secondary preventive measures such as eyewash stations or rinsing solutions are present in private households. Hence the consequences of such chemical injuries are often quite severe.

Ophthalmologists and general practitioners face challenges when chemical eye burns occur in the private as well as the industrial sector. As a general rule the patient who suffered the accident is washed with water right then and there, and this is "the best and most important first aid measure." In most cases the patient is then taken to an ophthalmologist or an emergency room; in rare cases to a general practitioner. In any case, regardless of the preliminary treatment and the caustic agent, the important thing is to rinse the eye burn right then and there. Typical rinsing solutions include substances available in any medical facility such as water, saline solution, Ringer's lactate and the like.

In places such as laboratories or industries using highly corrosive substances or in areas organized according to work safety factors, however, where chemical burns are a routine hazard, the proper solutions should be kept on hand in order to ensure optimum care with minimum adverse consequences.

Evolution of a chemical burn

All chemical burns follow the same pattern: a highly concentrated corrosive substance hits the surface of the eye. It then penetrates the eye by diffusion. As the substance penetrates deeper into the tissue, its concentration diminishes. If the concentration of the substance is high enough, it causes permanent tissue damage. This leads to necrosis.

The high ion concentration causes water to diffuse into the tissue (osmosis). The connective tissue swells (chemosis). Due to the extreme osmotic gradients, circulation is cut off completely: the blood vessels coagulate, removal of water from the blood vessels causes the red cells to condense therein, leading to acute vascular occlusion (stasis). The animal experiment with optical coherence tomography (OCT) of the anterior eye segment dramatically demonstrates that the penetration of sodium hydroxide in the corneal stroma is an event depending on concentration over time.

Given identical contact times, penetration depth and overall damage depend on concentration, as demonstrated by the OCT in the Ex Vivo Eye Irritation Test (EVEIT) [9,10]: the higher the concentration, the deeper the caustic agent penetrates into the cornea (Figure 3). The penetration of the substance, that is the ions, in the tissue changes the pH. Hydroxide ions were dramatically measured as marker ions for bases in the anterior chamber of the eye by the pH measurements of Rihawi [5]. With bases the increase of ions in the tissue takes place rapidly, e.g., within 80 seconds with 1 molar sodium hydroxide.

Case example:

28 year old female patient with severe sodium hydroxide burn

A 28 year old female patient was using a mordant to clean moss from cellar tiles in her home. As she was carrying the 10 liter bucket with dissolved sodium hydroxide tablets, an animal ran between her legs, causing her to trip. As she did so, the highly concentrated solution sloshed out of the bucket and completely soaked the left half of her face. She was taken to the emergency room, but without first performing an eye washing. The emergency room doctor merely applied a cotton pad soaked in saline solution and referred her to the nearest ophthalmology clinic. Upon admission to the ophthalmology clinic, her eye and facial skin were immediately washed with Previn solution (Previn-Lösung).

Diagnosis

- Black necrosis of the entire cheek, lid, and forehead skin
- Fish-eye syndrome
- Vessel interruptions in the entire conjunctiva spreading to a small region of the upper limbus.

Treatment

immediate:

- skin and eyelids rinse
- topical application of cortisone and Vitamin C

on day 1:

- skin necrosectomy
- 270° peridectomy
- 360° tenon plasty
- amnioplasty
- insertion of an Illig shell

Warning! Important: Previn is a completely different product from the Privin® familiar to ophthalmologists in this context!!! The main ingredient in Previn is Diphoterine®, whereas Privin contains naphazoline nitrate, which is no longer indicated for chemical burns.

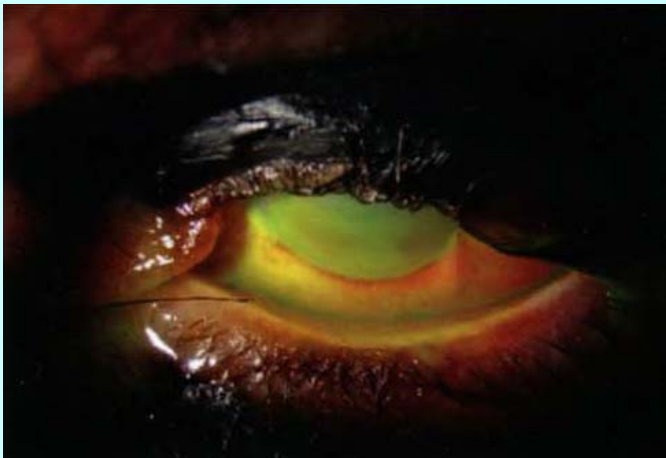


Figure 1: Extremely severe chemical burn from concentrated sodium hydroxide. First aid treatment with moist cotton pad, ca. 4 hour delay until adequate rinsing of the skin and eye. Eyelid necrosis with upper lid defect, black necrosis of the skin of the upper lid and nasal corner of the lid, necrosis of the entire cheek and forehead. Fish-eye syndrome with chemosis, vessel interruptions, and total erosion.

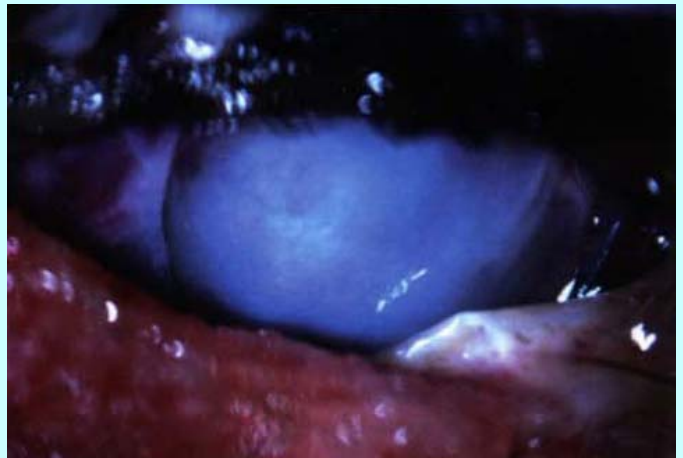


Figure 2: Clinical status following necrosectomy of the lower eyelid and cheek skin; corneal peridectomy, tenon plasty, and amnioplasty. An Illig shell was inserted as a placeholder.

Therapeutic considerations

In order to neutralize a highly concentrated base or acid, two essential processes must take place:

- Removal of any caustic substance remaining on the surface by washing.
- Neutralization ("rendering harmless") with an amphoteric wash solution, and decontamination of the active caustic substance in the tissue.

Short reaction time: long-lasting eyewashes

For accidents involving the surface of the eye and short reaction or residence times, performing long-lasting eyewashes with water, saline solution, and Ringer's lactate as soon as possible (within a few seconds) after a chemical burn is a proven and effective method that will prevent severe damage in many cases (Figure 4).

High concentration, long reaction time: decontamination of the tissue

With extremely highly concentrated corrosive substances and also with longer reaction or residence times, the corrosive substance penetrates into the tissue. A decontamination

of the inner tissue is therefore necessary. In order to reach these tissue layers, it is necessary to overcome an extreme osmolarity gradient. In the case of low osmolarity decontaminants such as tap water, this osmolarity gradient initially leads to water uptake and dilution in the tissue, but is not capable of transporting a neutralizing active substance to the damage site. Under these conditions, hyperosmolar solutions such as Previn are especially effective as tissue decontaminants. Rihawi effectively demonstrated this with the aid of neutralization curves for chemically burned corneas in diverse experiments performed on rabbit eyes. Statistics from the Merheim Hospital, where a total of 900 mild to severe chemical burn cases were treated at the burn centre from 2004 through 2009, are convincing clinical proof of the efficacy of this approach (Figure 5). The first aid rinsing solution was switched from Ringer's solution to Previn solution in 2006. We were able to reduce the number of hospital admissions and lengths of hospital stays for greater numbers of burn patients.

First aid at the ophthalmologist's: treatment of the whole disease

In the first aid provided by the ophthalmologist, therapeutic steps such as necrosectomy (peridectomy), tenon plasty, and amnioplasty are required to treat burns adequately. Depending on the course of the treatment, rehabilitative keratoplasty, limbal keratoplasty, and other procedures may be necessary as well.

Treatment of the whole disease is decisive. For example, in mechanical trauma with burns, as is typically the case in car accidents when the battery explodes, the possibility of retinal detachment must be considered. In a worst case scenario, vitreoretinal surgery with temporary kerato-prosthesis must be performed in the acute phase in order to preserve the patient's eyesight. Equally decisive is the treatment of acute burn-induced glaucoma. Particularly in the early stage of a burn, an undetected and hence untreated glaucoma can nullify any treatment success with the anterior eye segment. Furthermore, the at-times severe consequences of mechanical trauma in the sense of traumatic retinopathy must be taken into account.

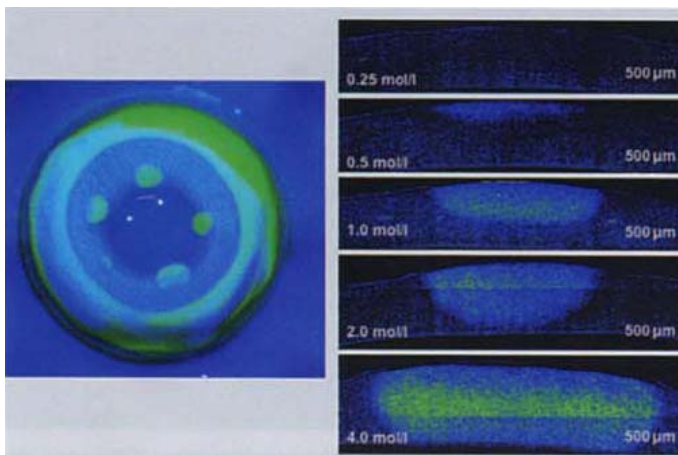


Figure 3: Multilocal Ex Vivo Eye Irritation Test: EVEIT on rabbit eye. Five different concentrations of sodium hydroxide were applied to the cornea for exactly 20 seconds [3]. For the same fluorescein-positive surface, the OCT scans revealed extreme differences in penetration depth and percent corneal burning. The amount of corneal burning is proportional to the concentration of the corrosive substance.

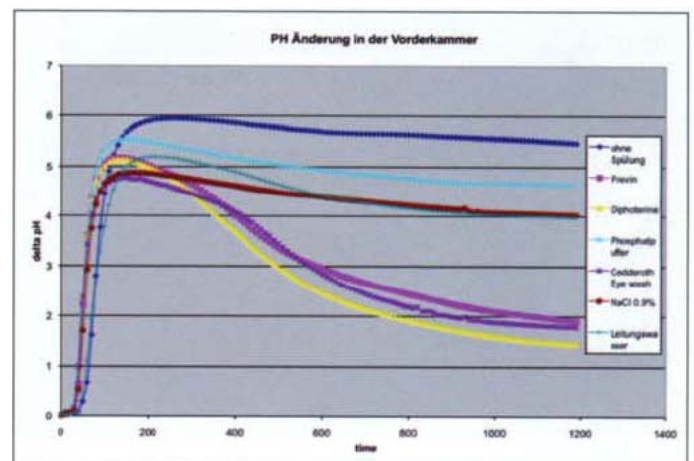


Figure 4: Efficacy of an eyewash solution after 20 seconds of sodium hydroxide burning followed with immediate rinsing. This figure shows that essentially all eyewash solutions bring about a change in pH. Water and saline solution are better than isotonic phosphate buffer. Cedderoth's Eye Wash and Previn solution, however, are notably superior to these substances.

Malpractice

Failure to wash a chemically burned eye at once endangers the patient's eyesight and I consider this as failure to provide assistance. Given the experimental and clinical results of delayed eyewashes, failure to wash has since been classified as grave malpractice [6]. In our ophthalmology clinic, initial washing takes priority over obtaining a patient history or taking care of the administrative details of admission. If the patient says he or she has suffered an ocular chemical burn, we proceed at once with a Previn solution eyewash. During the 15 minute wash there is always enough time to obtain a detailed patient history and to make a precise diagnosis.

Phosphate buffer washes

Experimental and clinical studies have demonstrated that using phosphate buffers to treat corneal erosion, a typical symptom of the corneal burn disease picture, usually leads to corneal calcification (Figure 6,7). Corneal calcifications render the cornea opaque and are thus diametrically opposed to the therapeutic goal of visual rehabilitation. They cause

an unacceptable side effect. Substances such as ph-neutral (Plum) or isotonic phosphate buffer formulations are therefore contraindicated in clinical practice [1, 4, 7, 8].

Emergency first aid

Essentially any cold beverage, except for those with high alcohol or acid contents, can be used as an emergency eye burn treatment, as such beverages reduce the amount of corrosive substance on the eye surface. Contrary to many textbook opinions, milk, beer, cola, lemonade, water, and lukewarm tea are also suitable as emergency treatments if the proper solutions are not on hand. At this point the therapeutic goal of removing the corrosive substance from the eye surface and the conjunctival sac has priority, hence nearly any aqueous, non-toxic, cool liquid is a viable option.

In the case of potentially contaminated liquids (stagnant water, liquids from used drink containers or bottles), an ophthalmologist must then wash the eye properly and apply a topical broad spectrum antibiotic for at least 3 days.

Medical and appropriate first aid

As appropriate first aid measures, Previn solution washes are indicated for accidents involving bases, acids, and oxidising-reducing and alkylating agents. Cederroth's Eye Wash Solution® is equally effective for contamination with bases. If these solutions are not available, tap water, Ringer's lactate, or sterile saline solution (Isogutt Akut®) can be substituted.

An initial wash with Previn should last 3 minutes, and at least 15 minutes in all other cases. We recommend using a clock or watch to time the eyewash accurately. It is critical to ensure adequate reserves of rinsing solution and to prevent the patient and the surrounding area from becoming soaked with liquid [containing the corrosive agent]. If both eyes are affected, we recommend simultaneous washing or washing each eye for short, alternating intervals. Furthermore, one should not forget personal protection (gloves), especially if hydrofluoric acid (HF) is involved. With hydrofluoric acid burns, even a small surface burn is all that it takes to cause severe cardiovascular complications.

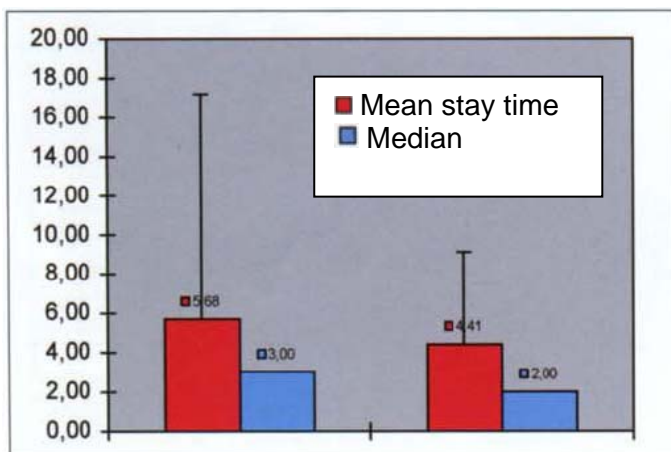


Figure 5: Change in the mean stay time of a chemical burn patient admitted to the Ophthalmology Hospital of Cologne-Merheim before (up until 2006; n= 56 patients) and after initial washing with Previn rinsing solution was started (since 2007; (n= 54 patients). The burn treatment protocol was otherwise unchanged. Admission criteria were erosion, chemosis, and presence of blood vessel interruptions; chemical burn greater than degree I according to the Reim classification.

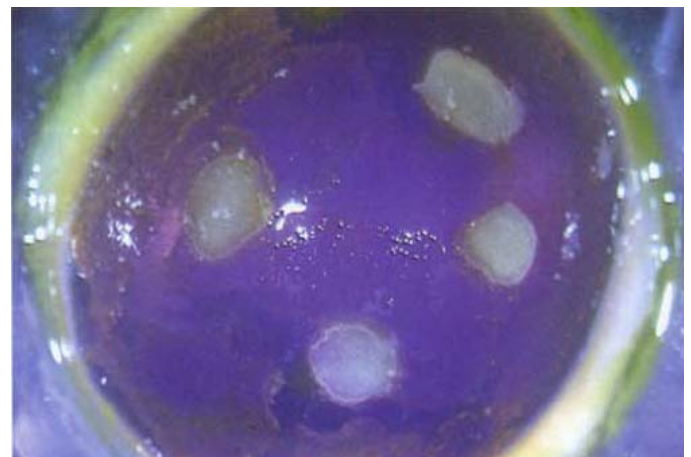

Figure 6: Eye drop therapy for experimentally-induced erosion on an isolated rabbit eye in the Ex Vivo Eye Irritation Assay. Eye drop therapy with phosphate-containing hyaluronate eye drops. Application of calcium-containing artificial tears led to surface calcification of the anterior corneal stroma within 2 days.

A special rinsing solution such as Anti-Flusssäure-Lösung should be used in such cases.

During the washing, eyelids are also everted and foreign particles (cement, lime) are removed mechanically.

Initial visit to the ophthalmologist or ophthalmology clinic

Depending on the Reim classification, for corneal erosion

or < 25% limbal involvement or clear cornea without vessel interruptions, we recommend outpatient treatment with an antibiotic, a steroid, and Vitamin C eyedrops, and checkups until the erosion has run its course. For more severe chemical injuries, we recommend hospital admission and therapy according to our established burn treatment guidelines (www.acto.de/service). Surgical therapy in a specialty clinic consists of tenon-, amnio-, and keratoplasty as well as limbal

stem cell transplants (Figure 8). Given the complexity of the treatment options, a treatment unit with experience in these therapies should be selected. A specialty clinic such as the Ophthalmology Clinic Cologne-Merheim or the University Ophthalmology Clinic in Halle is able to provide such services. These clinics have a research resource in the form of experienced teams who have been dedicated to research on novel therapy options for 20 years.

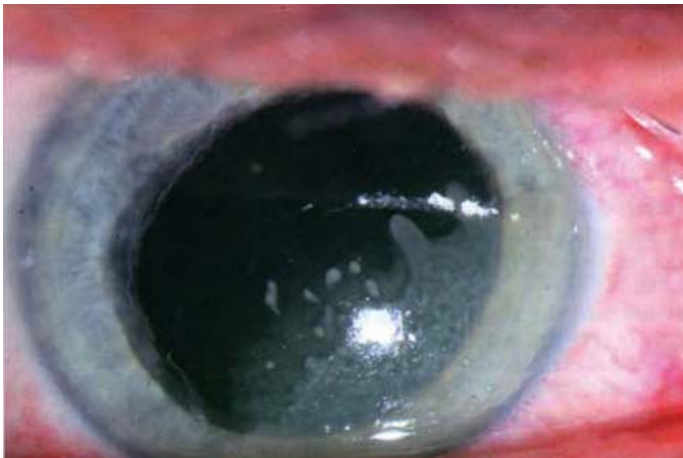

Figure 7: Zinc/sodium hydroxide solution-induced ocular burn. The burn was treated directly with Tima-Oculav® Eyewash Solution. This led to corneal calcification, which has persisted in the corneal stroma for one year. (Photo taken 2 weeks after the burn)

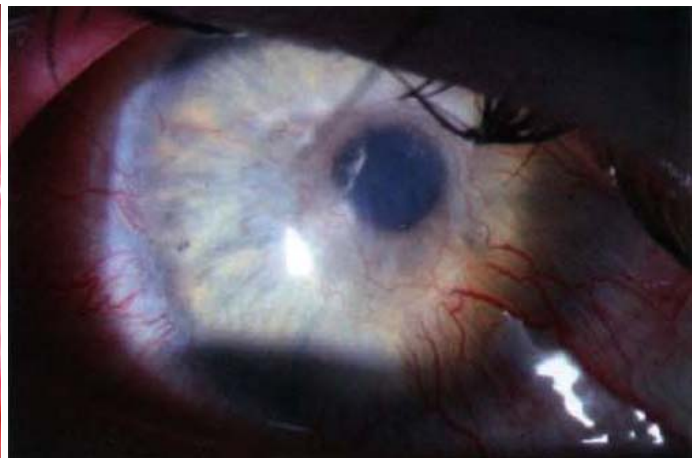


Figure 8: Chronic image of corneal vascularization with limbal stem cell deficiency and recurring erosion after corneal burning before and after extensive keratoplasty in combination with a limbal stem cell transplant from the same donor. Eyesight with far vision of 0.5 was restored after 1 year.

Previn solution (Previn-Lösung)

Previn is an amphoteric, chelating molecule occurring in aqueous solution. The purpose of the solution is to prevent chemical burns from occurring or to reduce the severity thereof.

As a chemical decontaminant, Previn solution brings about the following improvements:

- It stops the effect of irritants and corrosive substances on the eye and skin thanks to its amphoteric and chelating properties.
- It stops the chemical substance from penetrating deeper into the tissue: thanks to its hypertonicity, a backflow from the inner to the outer tissue is created.
- The pH quickly rises to 5.5 - 9, thus preventing any further chemical injury.
- After contact with the chemical substance, a longer intervention time is achieved with Previn versus water.

<http://www.prevocom/DE/sante/RisqueChimique/diphoterine/TvxRecDE.php>

Literature Cited

1. *Bernauer W et al (2006)* Corneal calcification following intensified treatment with sodium hyaluronate artificial tears. *Brit J Ophthalmol* 90: 285-288
2. *Bernauer W, Thiel MA, Langenauer UM, Rentsch KM (2006)* Phosphate concentration in artificial tears. *Graefes Arch Clin Exp Ophthalmol* 244: 1010-1014
3. *Frentz M, Goss M, Reim M, Schrage NF (2008)* Repeated exposure to benzalkonium chloride in the Ex Vivo Eye Irritation Test (EVEIT): observation of isolated corneal damage and healing. *ATLA* 36: 25-32
4. *Huige WM, Beekhuis WH, Rijnefeld WJ, Schrage NF, Remeijer L (1991)* Deposits in the superficial corneal stroma after combined topical corticosteroid and beta-blocking medication. *Eur J Ophthalmol* 1: 198-199
5. *Rihawi S, Frentz M, Schrage NF (2006)* Emergency treatment of eye burns: which rinsing solution should we choose? *Graefes Arch Clin Exp Ophthalmol* 244: 845-854
6. *Rihawi S, Frentz M, Becker J, Reim M, Schrage NF (2007)* The consequences of delayed intervention when treating chemical eye burns. *Graefes Arch Clin Exp Ophthalmol* 245: 1507-1513
7. *Schrage NF, Schlossmacher B, Aschenbrenner W, Langefeld S (2001)* Phosphate buffer in alkali eye burns as an inducer of experimental corneal calcification. *Burns* 27: 459-464.
8. *Schrage NF, Kompa S, Ballmann B, Reim M, Langefeld S (2005)* Relationship of eye burns with calcifications of the cornea? *Graefes Arch Clin Exp Ophthalmol* 243: 780-784
9. *Spöler F, Först M, Kurz H, Frentz M, Schrage NF (2007)* Dynamic analysis of chemical eye burns using high-resolution optical coherence tomography. *J Biomed Opt* 12: 041203
10. *Spöler F, Frentz M, Forst M, Kurz H, Schrage NF (2008)* Analysis of hydrofluoric acid penetration and decontamination of the eye by means of time-resolved optical coherence tomography. *Burns* 34: 549-555

Address all correspondence to:

**Prof. Norbert Schrage, M.D.
Municipal Hospital of Cologne-Merheim
Ophthalmology Department
Ostmerheimer Str. 200
51109 Cologne**

E-Mail: schragen@kliniken-koeln.de